

Original Research Article

Occurrence of *Demodex* infestation in chronic blepharitis in a tertiary care hospital in North-East India

Suranjana C. Hazarika¹, Himanto N. Hazarika^{2*}, Ashwini Ghuge²

¹Department of Microbiology, Gauhati Medical College and Hospital, Guwahati, Assam, India

²Regional Institute of Ophthalmology, Gauhati Medical College and Hospital, Guwahati, Assam, India

Received: 06 June 2021

Accepted: 21 June 2021

*Correspondence:

Dr. Himanto N. Hazarika,

E-mail: himanto5@yahoo.com

Copyright: © the author(s), publisher and licensee Medip Academy. This is an open-access article distributed under the terms of the Creative Commons Attribution Non-Commercial License, which permits unrestricted non-commercial use, distribution, and reproduction in any medium, provided the original work is properly cited.

ABSTRACT

Background: Chronic blepharitis is frequently encountered by ophthalmologists. *Demodex* mites (*Demodex folliculorum* and *Demodex brevis*) can play a role in its pathogenesis, especially in treatment-resistant cases. *Demodex* infestation often remains underdiagnosed and undertreated. Definitive diagnosis can be made with lash-sampling. Objective of the study was to find the association between *Demodex* infestation and chronic blepharitis.

Methods: The study included 80 patients diagnosed with chronic blepharitis and 80 controls without blepharitis. Four eyelashes were epilated from each lower and upper lids of the right and left eye (a total of sixteen samples) of each participant. Eyelash samples were examined under a light microscope and *Demodex* species were identified and counted.

Results: *Demodex* mites were detected in 45 cases (56.25%) and 14 controls (17.5%). Significant association was found between *demodex* infestation and blepharitis as odd's ratio was found to be 6.0612 and p value <0.0001. *D. folliculorum* was detected in 42 cases, *D. brevis* in 2 cases while in one case, both were detected. The mean age for *Demodex* positive cases and controls were 49.78±13.25 and 64±7.86 years, respectively. Amongst the cases, *Demodex* was detected in 57.69% males (30 out of 52) and 53.55% females (15 out of 28).

Conclusions: There is significant co-relation between *Demodex* infestation and chronic blepharitis. *Demodex* infestation should be part of the differential diagnosis of chronic blepharitis.

Keywords: Chronic blepharitis, *Demodex folliculorum*, *Demodex brevis*

INTRODUCTION

Demodex mites (Acari) are microscopic arthropod organisms belonging to the *Demodecidae* family of the *Trombidiformes* order.¹ *Demodex* mites are the most common microscopic ectoparasites found in the human skin. The rate of *Demodex* infestation increases with age, being observed in 84% of the population at age 60 and in 100% of those older than 70 years.²

Among more than 140 species of mites, only *D. folliculorum* and *D. brevis* are found on the human body.

D. folliculorum is approximately 0.3-0.4 mm long, while *D. brevis* is approximately 0.2-0.3 mm long.³ *D. folliculorum*, which has a long opisthosoma, lives alone or in groups in hair follicles and *D. brevis*, which has a short opisthosoma, lives mainly alone in sebaceous and meibomian glands. Their main food sources are follicular and sebaceous epithelial cells and sebum. They have a cigar-shaped body, a chitinous external skeleton, perforating mouthparts and four pairs of legs with a pair of claws at the terminal end.¹ Their life cycle is approximately 14-16 days long, they move mostly at night and they live in regions such as the sebaceous

glands in facial skin, including the nose, nasolabial folds, eyelids, cheek, forehead, chin and neck.⁴

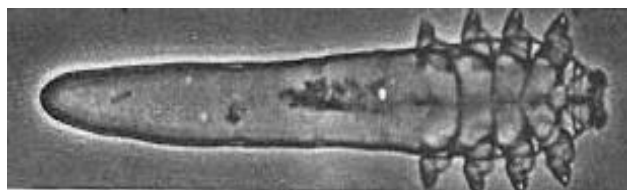


Figure 1: *D. folliculorum*; source: eyehealthHQ.



Figure 2: *D. brevis*; source: Medical News Today.

In ophthalmology, ocular demodicosis is typically accompanied by eyelash loss or abnormal alignment and chronic inflammation of the meibomian gland, leading to lipid tear deficiency in the conjunctiva.^{5,6} In turn, this deficiency leads to conjunctivitis and sight-threatening keratitis in the cornea.⁷ Several studies have also linked the presence of *Demodex* with chronic blepharitis because the mite can perpetuate the follicular inflammatory process.⁸⁻¹⁰

Chronic blepharitis is an ocular disease frequently encountered by ophthalmologists in clinical practices. Its treatment is difficult for both the patient and the physician because often it recurs despite being treated. Eyelash dandruff, adhesion of eyelashes, mild papillary conjunctivitis, meibomian gland dysfunction and telangiectasia may be seen in chronic blepharitis as well as irregularity of the lid edge in frequently recurring cases. *Demodex* mites can play a role in the pathogenesis of blepharitis along with bacterial agents, especially in treatment-resistant cases or recurrent cases after treatment.¹

Some researchers consider the mites to be merely passengers on skin because they are found on almost all normal adult skin and thus are coincidentally found on diseased skin.^{11,12} However, clinical observations have revealed that after ineffective conventional therapy, acaricidal therapy of these mites can eliminate the clinical symptoms of blepharitis.¹³

This study determined the occurrence of *Demodex* species on the eyelashes of subjects presenting with chronic blepharitis as well as those with normal eyelids. The identification of *Demodex* was done up to the species

level. The study also determined the relationship of the incidence of *Demodex* infestation with patient demographics.

METHODS

Our study was a hospital-based case control study. The study was done in the department of Microbiology, Gauhati Medical College and Hospital, which is a tertiary care hospital in Guwahati city in the state of Assam in North-East India. The study was conducted for a period of six months from July 2019 to December 2019.

The study population consisted of 80 patients diagnosed with chronic blepharitis attending outpatient department at Regional Institute of Ophthalmology, Gauhati Medical College and Hospital who were taken as cases and were termed as group A. Patients above 15 years of age and presenting with signs and symptoms of blepharitis such as itching, redness, burning, watering, blurring of vision and foreign body sensation in eyes were included as subjects in group A. Patients who had any ocular or systemic disease other than chronic blepharitis, who had undergone ocular surgery and who had received any systemic or topical treatment were excluded from the study.

80 healthy persons without any chronic or ocular disease were enrolled as controls and termed as group B. Controls were randomly selected from among volunteer participants. It was ensured that all cases and controls had similar demographic characteristics such as age, sex, ethnicity and samples were collected from both at about the same time. Sample size was calculated using Epi Info version 7.

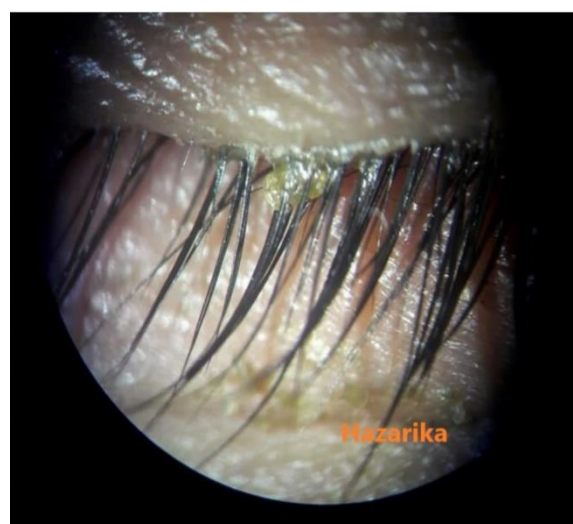

Figure 3: Blepharitis with cylindrical dandruff.

The diagnosis of blepharitis was made based on symptoms, clinical signs and ophthalmologic examinations. Blepharitis was diagnosed by evidence of lid margin or tarsal conjunctival erythema, bulbar conjunctival hyperaemia, telangiectasias, thickening or

irregularity of the eyelid margins or meibomian gland orifice inclusions.

Demodex infestation was diagnosed by identification of the parasite at the root of the lashes with light microscopy. Examination was done under slit lamp for presence of cylindrical dandruff (CD) which is considered to be an important sign of ocular demodicosis. Sample was collected using the lash sampling technique.¹⁴ Under aseptic conditions, four eyelashes were epilated with a sterile fine forceps from the upper and lower lids of both eyes of each participant under a slit-lamp biomicroscope and placed separately on each end of a glass slide, with a total of sixteen lashes on eight slides. The eyelashes were then covered with coverslips. 20 µl of normal saline was slowly pipetted at the edge of the coverslip. This was followed by 20 µl of 100% alcohol. Addition of alcohol was helpful especially in the presence of cylindrical dandruff as it caused the embedded *Demodex* to migrate out from it.

The counting time was prolonged up to 20 min in presence of cylindrical dandruff to allow the *Demodex* to migrate out. The slides were placed in sterile petri dishes and immediately transferred to the Microbiology laboratory.



Figure 4: Lash sampling technique.

The eyelash samples were examined under a light microscope. *Demodex* species (whether *D. folliculorum* or *D. brevis*) was identified on the basis of morphology. Presence of *Demodex* in at least one of the 16 epilated lashes was defined as *Demodex* positive. This was done for both the case group of chronic blepharitis patients and the healthy control group.

The data was collected and tabulated using Microsoft excel (Microsoft Corp., Redmond, WA, USA) and word (Microsoft Corp., Redmond, WA, USA). Microsoft word and excel were used to generate graphs and tables. Statistical evaluation of the data was performed using the SPSS 23.0 (statistical package for social sciences, Chicago, IL) program. Chi square test was used to evaluate categorical data. A $p < 0.05$ was considered to be statistically significant.

RESULTS

Out of the total 80 cases of chronic blepharitis, presence of *Demodex* mites was seen in 45 cases (56.25%). In the control group of 80, *Demodex* was detected in 14 participants (17.5%). In our study, significant association was found between *Demodex* infestation and chronic blepharitis as odds ratio was found to be 6.0612 and $p < 0.0001$.

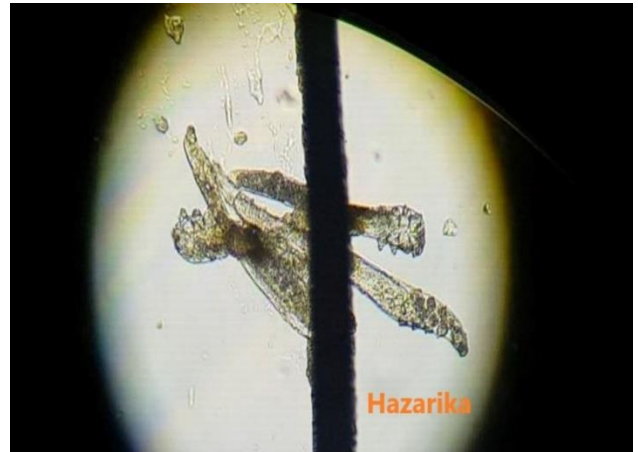

Figure 5: Cluster of four *D. folliculorum* against shaft of eyelash.




Figure 6: Two numbers of *D. folliculorum* against root of eyelash.

In group A, the species *D. folliculorum* was detected in 42 out of the 45 cases of *Demodex* infestation while *D. brevis* was detected in 2 cases out of a total of 45. Both *D. folliculorum* and *D. brevis* were detected in one case. In group B, all the 14 *Demodex* positives showed presence of *D. folliculorum*. No *D. brevis* was detected in the control group.

Out of the total of 80 cases of chronic blepharitis examined, the age group ranged from 17 to 83 years while it ranged from 18 to 78 years in group B comprising of healthy subjects. The mean age for *Demodex* positive cases and controls was 49.78 ± 13.25 (25-80) and 64 ± 7.86 (52-77) years respectively. It was observed that *Demodex* infestation increased with age in both the case and the control group. Another significant observation was that in the healthy subjects, occurrence of *Demodex* infestation was seen above 50 years of age (Table 1).

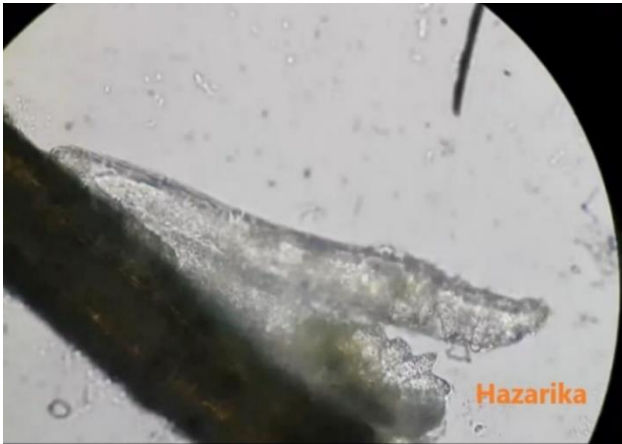


Figure 7: Presence of *D. folliculorum* and *D. brevis* in same patient.




Figure 8: *D. brevis* between two hair follicles.

Amongst the chronic blepharitis cases in group A, 52 were male patients and 28 were female patients. *Demodex* positivity was seen in 30 out of the 52 male patients (57.69%) while 15 out of the 28 female patients were *Demodex* positive (53.55%). The control group comprised of 50 male subjects and 30 female subjects. *Demodex* positivity was seen in 9 out of the 50 male participants (18%) and 5 out of the 30 female participants (16.67%). Thus, it was observed that gender did not have

significant influence on the occurrence of *Demodex* infestation in both the cases and the controls.

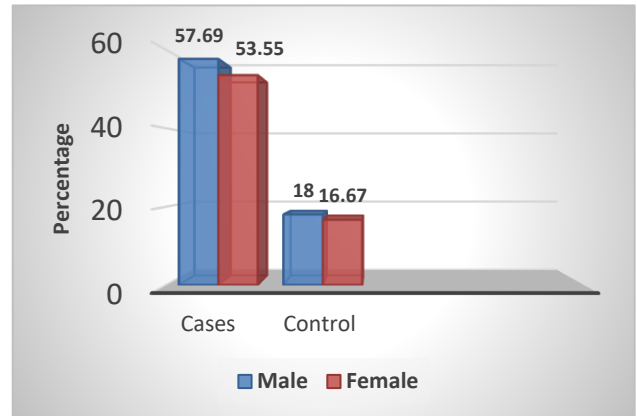


Figure 9: Occurrence of *Demodex* according to gender.

Table 1: Occurance of *Demodex* according to age.

Age group (in years)	Cases (group A)		Controls (group B)	
	Positive /total	Percentage	Positive /total	Percentage
15-20	0/2	0	0/2	0
21-30	5/14	35.71	0/15	0
31-40	5/12	41.67	0/10	0
41-50	13/22	59.1	0/23	0
51-60	15/21	71.43	6/19	31.58
61-70	3/4	75	4/6	66.67
71-80	4/4	100	4/5	80
81-90	0/1	0	-	-

DISCUSSION

Our study shows percentage of positivity of *Demodex* infestation in cases of chronic blepharitis to be 56.25% and that in healthy controls to be 17%. This pattern is seen to be similar to those seen in other parts of India and the rest of the world. A study by Zeytun et al in Erzincan, Turkey in 2019 showed a positivity of 79.2% in cases of blepharitis and 31.4% in healthy controls.¹ Another study by deVenecia and Siong in Manila, Phillipines in 2011 showed a positivity of 89.7% in patients with symptoms of blepharitis and meibomian gland dysfunction and 34% in healthy controls.¹⁵ Bhandari et al reported a positivity of *Demodex* in blepharitis cases and healthy controls to be 78.7% and 18% respectively in a study in Tamil Nadu, India in 2014.⁸ Though these other studies show higher infestation rate by *Demodex* especially in blepharitis cases, a meta-analysis of 13 studies from four countries (France, China, Germany and Turkey) by Zhao et al showed an infestation rate of 44.52% and 16.69% in blepharitis cases and healthy controls respectively, which is almost similar to the findings of our study.¹⁵ The higher infestation rate in other studies could be due to the fact that detection of *D. brevis* has been much less in our study.

Numerous epidemiological studies of *Demodex* mites have been performed in blepharitis patients as well as in healthy individuals and in patients of various diseases (Sümer et al 2000, Arici et al 2005, Kheirkhah et al 2007, Türk et al 2007, deVenecia et al 2011, Bhandari et al 2014, Altinkurt et al 2017 and Alver et al 2017).^{8,14,17-22} However, in most of the studies carried out, the *Demodex* species was not specified or mites were only identified up to the genus level. In this context, detection of the incidence as well as identification of the species of *Demodex* has been done in our study. It is expected that this will allow better understanding of the pathogenesis of the disease and better evaluation of the clinical picture.

Our study could detect only two cases of *D. brevis* in contrast to 42 cases of *D. folliculorum* while both *D. folliculorum* and *D. brevis* were detected in one case. *D. brevis* resides deep in the sebaceous and meibomian glands of eyes and face and are more difficult to extract out and visualise. A modification in methodology may be required in our study to detect more cases of *D. brevis*.

We have observed in our study that there is increased *Demodex* infestation with increase in age. This finding is consistent with other studies like those reported by Zeytun et al in Turkey in 2019 and Zhong et al in China, in 2019.^{1,23}

In our study, we did not observe any significant influence of gender on the occurrence of *Demodex* infestation. This is not in agreement with the findings of Zhong et al in China in 2019 (who has reported higher infestation in females) and the findings of Elston et al in USA in 2014 (who has reported higher infestation in males).^{23,24}

CONCLUSION

There is a definite co-relation between *Demodex* mite infestation in our eyes and eyelashes and occurrence of chronic blepharitis. Demodicosis may masquerade as a number of other ocular conditions leading to misdiagnosis and ineffective treatment. *Demodex* should be a top differential diagnosis in the management of chronic blepharitis. Definitive diagnosis is done by lash sampling, that is by epilation and simple microscopy. Further long-term study is required to understand the effects of *Demodex* mites on the human body.

ACKNOWLEDGEMENTS

We would like to thank the doctors and staff of Regional Institute of ophthalmology, Gauhati Medical College and Hospital for their help and support during the study, Lahari Saikia, HOD, Department of Microbiology, Gauhati Medical College and Hospital, Dipali C. Deka, director and HOD, Regional Institute of Ophthalmology, Gauhati Medical College and Hospital, for their guidance and encouragement throughout the study and the Principal, Gauhati Medical College and Hospital for

giving us permission to conduct the study in Gauhati Medical College and Hospital.

Funding: No funding sources

Conflict of interest: None declared

Ethical approval: The study was approved by the Institutional Ethics Committee

REFERENCES

1. Zeytun E, Karakurt Y. Prevalence and load of *Demodex folliculorum* and *Demodex brevis* (Acari: Demodicidae) in patients with chronic blepharitis in the province of Erzincan, Turkey. J Med Entomol. 2019;56(1):2-9.
2. Post CF, Juhlin E. *Demodex folliculorum* and blepharitis. Arch Dermatol. 1963;88:298-302.
3. Horvath A, Neubrandt D, Ghidan A, Nagy K. Risk factors and prevalence of *Demodex* mites in young adults. Acta Microbiol Immunol Hung. 2011;58(2):145-55.
4. Gao YY, Pascuale MAD, Li W, Liu DT, Baradaran-Rafii A, Elizondo A, et al. High prevalence of *Demodex* in eyelashes with cylindrical dandruff. Invest Ophthalmol Vis Sci. 2005;46(9):3089-94.
5. Patel KG, Raju VK. Ocular demodicosis. W V Med J. 2013;109(3):16-8.
6. Chen W, Plewig G. Human demodicosis: revisit and a proposed classification. Br J Dermatol. 2014;170(6):1219-25.
7. Lee SH, Chun YS, Kim JH, Kim ES, Kim JC. The relationship between *Demodex* and ocular discomfort. Invest Ophthalmol Vis Sci. 2010;51(6):2906-11.
8. Bhandari V, Reddy J. Blepharitis: always remember *Demodex*. Middle East Afr J Ophthalmol. 2014;21(4):317-20.
9. Galea M, Sharma R, Srinivasan S, Roberts F. *Demodex* blepharitis mimicking eyelid sebaceous gland carcinoma. Clin Exp Ophthalmol. 2014;42(2):208-10.
10. Laspina F, Samudio M, Arrua M, et al. *Demodex* spp in patients with chronic blepharitis. Chile J Infectol. 2015;32(1):37-42.
11. Kemal M, Sumer Z, Toker MI, Erdogan H, Topalkara A, Akbulut M. The prevalence of *Demodex folliculorum* in blepharitis patients and the normal population. Ophthalmic Epidemiol. 2005;12(4):287-90.
12. Talghini S, Fouladi DF, Babaeinejad S, Shenasi R, Samani SM. *Demodex* mite, rosacea and skin melanoma; coincidence or association? Turkiye Parazitol Derg. 2015;39(1):41-6.
13. Turk M, Ozturk I, Sener AG, Kuçukbay S, Afsar I, Maden A. Comparison of incidence of *Demodex folliculorum* on the eyelash follicle in normal people and blepharitis patients. Turkiye Parazitol Derg. 2007;31(4):296-7.
14. Coston TO. *Demodex folliculorum* blepharitis. Trans Am Ophthalmol Soc. 1967;65:361-92.

15. Venecia ABD, Siong RLB. Demodex sp. infestation in anterior blepharitis, meibomian-gland dysfunction, and mixed blepharitis. *Philipp J Ophthalmol*. 2011;36:15-22.
16. Zhao YE, Wu LP, Hu L, Xu JR. Association of blepharitis with Demodex: a meta-analysis. *Ophthalmic Epidemiol*. 2012;19(2):95-102.
17. Sümer Z, Arıcı MK, Topalkara A, Özçelik S, Yıldırım S. Prevalence of Demodex folliculorum in patients with chronic blepharitis. *Cumhuriyet Med J*. 2000;22:69-72.
18. Arıcı M.K, Sümer Z, Toker MI, Erdoğan H, Topalkara A, Akbulut M. The prevalence of Demodex folliculorum in blepharitis patients and the normal population. *Ophthalmic Epidemiol*. 2005;12:287-90.
19. Kheirkhah A, Casas V, Li W, Raju VK, Tseng SC. Corneal manifestations of ocular Demodex infestation. *Am J Ophthalmol*. 2007;143(5):743-9.
20. Türk M, Oztürk I, Sener AG, Küçükbay S, Afşar I, Maden A. Comparison of incidence of Demodex folliculorum on the eyelash follicle in normal people and blepharitis patients. *Türkiye Parazitoloji Dergisi*. 2007;31(4):296-7.
21. Altınkurt E, Müftüoğlu O, Uğurlu A, İstanbullu-Tosun A, Aydın R, Avcı O. To investigate the relationship between the grade of blepharitis with presence of Demodex spp. in patients with chronic anterior blepharitis. *Türkiye Klinikleri J Ophthalmol*. 2017;26:181-6.
22. Alver O, Kıvanç SA, Budak BA, Tüzemen NU, B, Özmen AT. A clinical scoring system for diagnosis of ocular demodicosis. *Med Sci Monit*. 2017;23:5862-9.
23. Zhong J, Tan Y, Li S, Peng L, Wang B, Deng Y, et al. The prevalence of Demodex folliculorum and Demodex brevis in cylindrical dandruff patients. *J Ophthalmol*. 2019;2019:8949683.
24. Elston CA, Elston DM. Demodex mites. *Clinic Dermatol*. 2014;32(6):739-43.

Cite this article as: Hazarika SC, Hazarika HN, Ghuge A. Occurrence of Demodex infestation in chronic blepharitis in a tertiary care hospital in North-East India. *Int J Community Med Public Health* 2021;8:3322-7.