

Original Research Article

Evaluation of Bohicon cotton ginning factory workers respiratory health using chest radiography

Hubert C. Hounsossou^{1*}, Patricia Yekpe Ahouansou², Malomon A. Bonou¹,
Nazifatou R. Babadjide¹, Napelis M. O. Tidjani¹, Olivier Biauou²

¹Non-Communicable Diseases and Cancer Research Unit, Laboratory of Applied Biology Research, Polytechnic School of Abomey-Calavi, University of Abomey-Calavi, Abomey-Calavi, Benin

²Medical imaging department of the CNHU HKM of Cotonou, University of Abomey-Calavi, Benin

Received: 04 January 2021

Revised: 31 January 2021

Accepted: 02 February 2021

*Correspondence:

Dr. Hubert C. Hounsossou,

E-mail: hchube1963@gmail.com

Copyright: © the author(s), publisher and licensee Medip Academy. This is an open-access article distributed under the terms of the Creative Commons Attribution Non-Commercial License, which permits unrestricted non-commercial use, distribution, and reproduction in any medium, provided the original work is properly cited.

ABSTRACT

Background: Chest radiography is widely used to monitoring the occupational lung disease caused by the inhalation or ingestion of dust particles. Our goal was to explore the respiratory system disease among cotton ginning workers at Bohicon using radiography.

Methods: We performed cross-sectional descriptive from February 25 to June 11, 2015. It included 110 cotton ginners selected from the 416 workers of ginning factory. The study participant underwent a survey and a postero-anterior chest X-ray, respectively. Radiographic examinations were performed with a conventional radiographic device. The radiograms were acquired on analog and were developed with automatic processor. The interpretation has been performed by a radiologist. We performed the data analysis with Epi Info 6.5 software.

Results: The mean age of our sample is 33.96 ± 4.22 years with a minimum age of 19 and a maximum of 56 years. Also, it should be noted that 89.1% of workers had between one year and 10 years of work experience. Chest tightness and cough are the most respiratory symptoms raised among its workers. 78.18% of workers said they had cough and 55.45 admitted to having chest tightness. Bronchial lesion was the most observed (70.90%) followed by plural lesion (07.26%). Only seven (07) over 110 (7.28%) participants had a lung lesion.

Conclusions: In according our result, chest radiography could be used to respiratory health monitoring for the highlighting bronchial, lung and pleural lesion. A large case-control study will be performed to confirm our findings about this population.

Keywords: Cotton dust, Radiography, Chest

INTRODUCTION

The human organism, far from being autonomous, is seriously influenced by the environment in which it lives. Breathing is one of the most important functions of the organism, which is only possible thanks to the various mechanisms of the respiratory system.¹ The lungs are in fact organs of respiration that are constantly exposed to the risks associated with our environmental dust.

Today's industrial workers suffer of the variety illnesses caused by the workplace's dust.² About the textile industry it is large well-known that the cotton dust is responsible for byssinosis and other respiratory disease.³⁻⁵ In African countries, the textile sector is one of industrialized sector that employs a large number of workers.⁶ Despite this reality, there are limited number of publications in the literature specifically on respiratory disease for the cotton ginners who are submitted to cotton

dust. The few authors who have addressed the health problem among cotton ginner workers, their studies were focused on clinical aspect.⁷⁻⁹ Recently Kanko et al, performed an evaluation of respiratory status of textile factory workers exposed at cotton dust in Ethiopia using spirometer and clinical investigation survey. This study revealed that respiratory diseases and functional troubles of lungs in the target population.¹⁰ In other developing countries similar studies were performed using chest radiographic test in addition to functional respiratory test. They recorded some lungs and bronchial lesion on chest radiography.^{3,11}

Chest radiography is widely used to monitoring the occupational lung disease caused by the inhalation or ingestion of dust particles.¹² Also, the fact that cotton ginning is seasonal activity which take place in rural area away from specialized hospitals, the chest radiography which available in peripheral hospital could be help for the health monitoring for cotton ginning factory workers.

Our study aims to explore the respiratory system disease among cotton ginning workers at Bohicon (Benin) using radiography test. To achieve our goal, we performed a chest radiography for 110 workers selected in cotton ginner factory at Bohicon.

METHODS

This cross-sectional descriptive study took place from February 25 to June 11, 2015 at Bohicon cotton ginning factory and Abomey departmental hospital. Our sample consisted of 110 cotton ginning workers selected from 410 workers of this factory. The 110 subjects were the volunteer workers respecting our inclusion criteria that were: workplace subject to cotton dust (cotton sorting place, Cotton ginning place, cotton packing place); have participated at least two years of cotton ginning campaign and workers who accepts to undergo a chest radiography.

We exclude all workers who had a history of diagnosed respiratory disease and workers who practice other activity which generate an organic dust. Also, office workers of this factory were excluded. All step of our sample constitution was summarized in Figure 1.

The subjects selected for study underwent a survey and a postero-anterior chest X-ray, respectively. Data were collected using survey forms and followed by a radiographic examination. Survey served us to collect socio-demographic data and functional respiratory symptoms.

Radiographic examinations were performed with a conventional General Electric Proteus radiographic device. The images were acquired on analog film in 35x43 cm format and were developed with an Agfa automatic processor. Finally, the interpretation has been performed by a radiologist. We performed the data analysis with Epi Info 6.5 software.

About an ethical precaution, we obtained the authorization from the factory authorities, also the consent of the workers included in the study. We performed all data collection under anonymity.

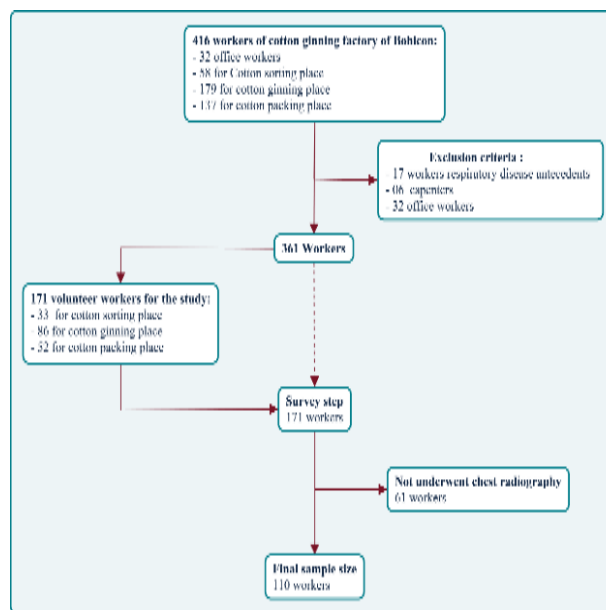


Figure 1: Flowchart for the study sample constitution.

RESULTS

Our sample consisted of 110 workers from the Bohicon ginning factory, including 1 woman and 109 men. The mean age of our sample is 33.96±4.22 years with a minimum age of 19 and a maximum of 56 years. Also, it should be noted that 89.1% of workers had between one year and 10 years of work experience (Table 1). Chest tightness and cough are the most respiratory symptoms raised among its workers. 78.18% of workers said they had cough and 55.45 admitted to having chest tightness. Dyspnea was the least observed as respiratory symptoms, only 35% of workers presented it (Table 2). After the interpretation of the chest X-ray, pulmonary, bronchial and plural lesions were observed. Bronchial lesion was the most observed (70.90%) followed by plural lesion (07.26%). Only seven (07) over 110 (7.28%) participants had a lung lesion (Table 3).

Table 1: Socio-professional characteristic of our participants.

Variables	Minimum	Moyenne ±IC	Maximum
Age (ANS) (year)	19	33.96±5.2	56
Ancienneté (ANS)	1-10	11-20	20+
Fréquence Absolue	98	11	1
Fréquence Relative	89.1	10	0.9

Table 2: Respiratory functional symptoms of cotton ginning workers.

Variables		Number	Percent (%)
Chest	Positive	61	55.45
	Négative	49	44.55
Tightness	Positive	86	78.18
	Négative	24	21.81
Cough	Positive	35	31.81
	Négative	75	68.18
Dyspnea	Positive	35	31.81
	Négative	75	68.18

Table 3: Chest radiographic lesion of cotton ginning workers.

Radiographic lesion	Number	Percent (%)
Bronchial	78	70.90
Plural	8	7.28
Lungs	7	6.36
Normal	17	15.46
Total	110	100

DISCUSSION

This preliminary study aims to assess the importance of chest radiography for cotton ginner worker respiratory problem monitoring. We enrolled 110 cotton ginning workers of Bohicon factory composed of 109 men and a woman. The subject of our sample had been submitted to an investigation survey and underwent a chest radiography. The age of workers was ranged between 19 years and 56 years and 89.1% of workers had between one and ten years of employment. These findings show that the young persons are more solicited in textile factory due to physical effort required the factory's activities. Our age range is nearly what Kanko et al recorded, from 21 to 50 years, in their study in Ethiopia.¹⁰ Similar finding (age range: 18 to 52 years) had been reported by Ahasan et al in textile factory at Bangladesh.¹³

Several authors before us, recorded an important prevalence of respiratory symptoms over textile factory workers. The respiratory symptoms reported were cough, phlegm, chest tightness and dyspnea.^{7,14-17} In our study the main respiratory symptoms observed among our participant were cough, chest tightness and followed by dyspnea. Our result is agreement with Bakke, Al-Neaimi and Raza et al, who raised cough as the important respiratory symptom.¹⁸⁻²⁰ Unlike our study dyspnea had been reported as the important respiratory symptom by Ghasemkhani et al and Alemu et al in respective studies.^{15,21}

About to our chest radiography findings, we recorded 70.90% of bronchial lesion which was exclusively bronchial wall thickening. Other this radiography lesion we recorded plural (07.28%) lesion and lung lesion (06.36%). Our result is agreement with the finding of Mansouri et al study who reported a high rate of bronchial wall thickening (31%) and 8% of lung lesion.³

In addition to raise bronchial wall thickening as the most chest radiography lesion, their found a statistically significant difference about this lesion between cotton ginner workers and office workers. Unlike us, Jannet and Jeyanthi recorded 28.8% of mild variation and 3.9% severe obstructive lung disease.¹¹

Our study presents some limitations. The subjects who had been included in this study were volunteers, they were not selected by the probabilistic technical. Also, we were used analogic radiographic image. Digital radiographic image gives more information than the analogic system image.

CONCLUSION

This preliminary study performed on cotton ginning workers of Bohicon factory allowed to highlight in majority bronchial lesion (70.9%). Chest radiography could be used to respiratory health monitoring for the highlighting bronchial, lung and pleural lesion. A large case-control study will be performed to confirm our findings about this population.

ACKNOWLEDGEMENTS

Authors would like to thank Bohicon cotton ginning factory authorities and its medical staff, and all participants for their valuable time and cooperation in providing the necessary information.

Funding: No funding sources

Conflict of interest: None declared

Ethical approval: The study was approved by the Institutional Ethics Committee

REFERENCES

1. Marieb EN, Hoehn K, Desbiens A, Dupont S, Dubé S. Anatomie et physiologie humaines 6th ed, Montréal (Québec) Canada : Pearson ERPI. 2019.
2. WHO. Exposition à certaines poussières végétales: limites recommandées d'exposition professionnelle à visée sanitaire : rapport. Organisation mondiale de la santé. 1983.
3. Mansouri F, Pili JP, Abbasi A, Soltani M, Izadi N. Respiratory problems among cotton textile workers. *Lung India*. 2016;33(2):163-6.
4. Heyden S, Pratt P. Exposure to Cotton Dust and Respiratory Disease: Textile Workers, 'Brown Lung,' and Lung Cancer. *JAMA*. 1980;244(16):1797-8.
5. Bouhuys A, Wolfson RL, Horner DW, Brain JD, Zuskin E. Byssinosis in Cotton Textile Workers. *Ann Intern Med*. 1969;71(2):257-69.
6. Yülek MA, Yağmur MH. Textile and Clothing Sector, and the Industrialization of Sub-Saharan Africa. In: Efobi UR, Asongu S, eds. *Financing Sustainable Development in Africa*. Springer International Publishing; 2018:421-50.

7. Osibogun A, Oseji MI, Isah EC, Iyawe V. Prevalence of byssinosis and other respiratory problems among textile mill workers in Asaba, Nigeria. *Niger Postgrad Med J*. 2006;13(4):333-8.
8. Laraqui CH, Rahhali A, Laraqui O. Byssinose et asthmes professionnels chez les ouvriers exposés aux poussières de coton. *Revue Française d'Allergologie et d'Immunologie Clin*. 2002;42(2):133-41.
9. Amri C, Henchi MA, Abdallah B, L Bouzgarrou, N Chaari, M Akrouf et al. Dépistage participatif des risques professionnels dans l'industrie du textile tunisienne. *Archives des Maladies Professionnelles et de l'Environnement*. 2009;70(2):163-72.
10. Kanko T, Shibru G, Gebremeskel F, Boda B, Girma E. Assessment of respiratory status among workers exposed to cotton dust at Arba Minch Textile Factory, Southern Ethiopia. *IJMMS*. 2017;9(11):126-36.
11. Jannet J, Jeyanthi G. Pulmonary health status of ginning factory women laborers in Tirupur, India. *Indian J Occupational Environmental Med*. 2006;10(3):116.
12. Kim K-I, Kim CW, Lee MK, Lee KS, Park CK, Choi SJ. Imaging of Occupational Lung Disease. *Radio Graph*. 2001;21(6):1371-91.
13. Ahasan MR, Ahmad SA, Khan TP. Occupational exposure and respiratory illness symptoms among textile industry workers in a developing country. *Appl Occup Environ Hyg*. 2000;15(3):313-20.
14. Fantahun M, Abebe Y. Self-reported disease conditions among workers of the textile mill in Bahir Dar, Northwest Ethiopia. *EJHD*. 1999;13(2):151-6.
15. Alemu K, Kumie A, Davey G. Byssinosis and other respiratory symptoms among factory workers in Akaki textile factory, Ethiopia. *Ethiop J Health Devel*. 2010;24(2):133-9.
16. Nagoda M, Okpapi JU, Babashani M. Assessment of respiratory symptoms and lung function among textile workers at Kano Textile Mills, Kano, Nigeria. *Nigerian J Clin Practice*. 2012;15(4):373.
17. Abebe Y, Seboxa T. Byssinosis and other respiratory disorders among textile mill workers in Bahr Dar northwest Ethiopia. *Ethiop Med J*. 1995;33(1):37-49.
18. Raza SN, Fletcher AM, Pickering CA, Niven RM, Faragher EB. Respiratory symptoms in Lancashire textile weavers. *Occup Environ Med*. 1999;56(8):514-9.
19. Al-Neaimi YI, Gomes J, Lloyd OL. Respiratory illnesses and ventilatory function among workers at a cement factory in a rapidly developing country. *Occupational Med*. 2001;51(6):367-73.
20. Bakke P, Eide GE, Hanao R, Gulsvik A. Occupational dust or gas exposure and prevalences of respiratory symptoms and asthma in a general population. *Eur Respir J*. 1991;4(3):273-8.
21. Ghasemkhani M, Kumashiro M, Rezaei M, Anvari AR, Mazloumi A, Sadeghipour HR. Prevalence of Respiratory Symptoms among Workers in Industries of South Tehran, Iran. *Industrial Health*. 2006;44(2):218-4.

Cite this article as: Hounsossou HC, Yekpe PA, Bonou MA, Babadjide NR, Tidjani NMO, Biao O. Evaluation of Bohicon cotton ginning factory workers respiratory health using chest radiography. *Int J Community Med Public Health* 2021;8:1043-6.