

Case Report

Efficacy of vision therapy in impaired stereoscopic depth with intermittent exotropia (true divergence excess) with unilateral amblyopia: a case report

Reena Gupta¹, Richa Jangra^{2*}, Gaurav Dubey³, Ramesh Hooda⁴, Nirmal Parmar⁴

¹Associate Professor, ²Optometry Intern, ⁴Lecturer, Department of Paediatric Ophthalmology, Regional Institute of Ophthalmology, PGIMS, Rohtak, Haryana, India

³Optometry Resident, Faculty of Paramedical Sciences, UPUMS, Saifai, Etawah, Uttar Pradesh, India

Received: 04 December 2019

Accepted: 25 December 2019

*Correspondence:

Richa Jangra,

E-mail: richa999215@gmail.com

Copyright: © the author(s), publisher and licensee Medip Academy. This is an open-access article distributed under the terms of the Creative Commons Attribution Non-Commercial License, which permits unrestricted non-commercial use, distribution, and reproduction in any medium, provided the original work is properly cited.

ABSTRACT

Divergence excess (DE) can be described clinically as exotropia at far greater than the near deviation by at least 10 prism dioptres (PD). We are reporting a rare case of 25-year-old female visited in the eye department for a routine eye check-up with a history of decreased vision in one eye. On examination, it was detected as a case of unilateral amblyopia with intermittent exotropia of true divergence excess with high accommodative-convergence over accommodation (AC/A) ratio. The patient was asymptomatic from exo-deviation due to the presence of binocular vision and good fusional reserve. The patient was started on active conventional vision therapy along with occlusion therapy. Post 16 weeks of constant therapy, a vision assessment with complete squint assessment along with binocular vision tests were performed. The result interprets to support the use of active conventional vision therapy as an integral part of the clinical treatment of amblyopia and intermittent exotropia. The rate of recovery of several monocular functions monitored during the vision therapy period provides the evidence of neural plasticity at multiple sites in the visual pathway in this adult amblyope. Therefore, if an ordered plan is being followed for the management of the patient of unilateral amblyopia and divergence excess, it can yield long-lasting improvement in visual acuity and binocular functions of any age.

Keywords: Divergence excess, Intermittent exotropia, Neural plasticity, Amblyopia, AC/A ratio, Active conventional vision therapy

INTRODUCTION

Divergence excess (DE) can be described clinically as exophoria at distance greater than the near deviation by at least 10 prism dioptres (PD).¹ Cooper and Medow discussed the possibility that the chances of high accommodation convergence to accommodation ratio could function in intermittent exotropia which might have normal accommodative-convergence over accommodation (AC/A) ratio or somewhat higher than normal.² Kushner revealed in his study that about 60% of patients (approx.) have high AC/A ratio with true divergence excess and the

remaining 40% had a normal AC/A ratio.³ Rogers describes stereopsis as a depth of perception and 3-dimensional structure obtained by individual ocular information from both eyes with normally developed binocular vision.⁴ Charles Wheatstone first initiated and explained the phenomena that the brain record and perceive the 3-dimensional object by 2 different views projected by it on the 2 retinae.⁵ He further concluded that the object from different distance project images that differ in their horizontal position from 2 eyes giving the depth cue of retinal disparity.⁶

Deficiency in stereopsis can be complete or more or less impaired mainly because of amblyopia and strabismus. Webber and wood demonstrate the impaired stereoscopic depth perception is the common deficit associated with amblyopia under common viewing conditions.⁷ Several studies encompass perceptual activities with amblyopic children and adults. Polant study shows improved scores on Snellen's acuity and contrast sensitivity with no follow-up post protocol completion on 5 amblyopic childrens.⁸ A similar improvement was also observed in Li study in which perceptual learning was compared with patching in children. However, perceptual learning required less time to achieve similar results.⁹

Additionally, recent studies suggest extensive plasticity in the visual system of adults with amblyopia.¹⁰⁻¹² Perceptual learning techniques with adults show improvement with visual detection, stereo information and contrast sensitivity function.^{8,13} Many case reports demonstrate that vision therapy works for treating amblyopia in adults and children.^{14,15}

For many years, it was believed that amblyopia was only amenable to treat up to seven or eight years. Scientific research by the National Eye Institute, National Institutes of Health, and Department of Health and Human Services have now proven that effective treatment can take place up to the age of 17. Scientific research on treatment after the age of 17 has not even so done.

Case description

The study was conducted in the Paediatric Ophthalmology and Strabismus outpatient department (OPD) in Regional Institute of Ophthalmology (RIO) (PGIMS) Rohtak, Haryana. The verbal consent for conducting this study was obtained from the concerned participant. A rare case of 25 years old moderately built female visited in eye OPD for routine Ocular examination with a history of decreased vision in one eye with symptom of headache. The investigative report reveals left unilateral amblyopia with intermittent exotropia (true divergence excess). The patient refused for squint surgery.

CASE REPORT

Examination

On carefully examining the patient, it was found that the patient had moderate unilateral amblyopia with 6/6 in right and 6/18 in left eye with no improvement with the pin-hole. The fundus examination was within the normal limits. The further examination report reveals the straight head-posture.

Intervention

Out of 16 weeks program, the intervention started initially with the occlusion therapy for a period of 5 weeks by occluding the right dominant eye 4-6 working hours daily

in order to prepare the eye for squint surgery. Through this therapy, the patient's visual acuity progressively improved from 6/18 to 6/12 (P). Post 5 week, the ophthalmologist planned for surgery which was refused by the patient. The next phase of treatment was an active conventional vision therapy with appropriate refractive correction, RAF (Royal Air Force) rule to enhance convergence and accommodation, Brock string for 2-4 hours for a period of 1 week (Figure 1). After 1 week, the complete vision therapy of 10 weeks (3 times a week, 15 min session per exercise in OPD) was done by using RAF rule, vectogram to enhance depth perception, brock string, and synaptophore (Figure 2) (Table 1). The occlusion therapy was not continued during the vision therapy period.



Figure 1: Royal air force rule.

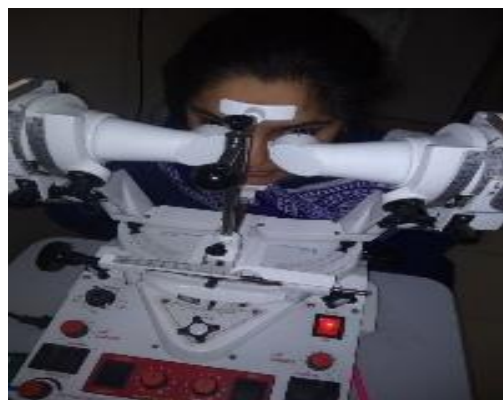


Figure 2: Synaptophore.

Table 1: The participant's 16 weeks regime.

5 (weeks)	1 (week)	10 (weeks) three times a week
4-6 hours of occlusion therapy	2-4-hour occlusion therapy and vision therapy (RAF rule and Brock string)	Complete vision therapy (RAF rule, Brock string, vectogram and synaptophore)

Outcome measurement

The patient was carefully assessed in eye OPD by an eye-screening method addressing all important aspects with an

evaluation done in 3 visits. The patient had unilateral amblyopia in left eye. In visit-1, the left divergent squint was observed (Table 2). In visit-2, the occlusion therapy of 5 weeks started. The patient had alternate fixation with improvement in left eye. After the completion of 1-week vision therapy, the alternate divergent squint reduces and exophoria remains which disappears in the last third visit of vision therapy.

Table 2: One-month follow-up followed by 1st visit.

1.	Repetitions of squint workup
2.	Surgeon plan for surgery but patient refuses
3.	Plan for vision therapy

The visual acuity, oculus dextrus (OD) and oculus sinister OS were measured by using various tools like refraction, cyclopegic refraction, cover-uncover test, extra-ocular movements, near point convergence and accommodation

by RAF rule, binocular single vision (BSV) using tool synaptophore for Grade I and II and titmus fly for near Grade III and randot test for distance Grade III (Tables 3 and 4).

Table 3: Visual acuity of left and right eye followed by 16 weeks of intervention.

Visual acuity	Visit-I (5 week)	Visit-II (1 week)	Visit-III (10 week)
Left eye	6/18	6/12 (P) followed by 6/9	6/6 (P) with snellen chart 6/6 with single letter optotype (SLO)
Right eye	6/6	6/6	6/6

Table 4: Screening of visual acuity OD and OS from initiation till post completion of convention vision therapy following I, II, and III visit.

Visual acuity OD and OS		16 weeks intervention		
		Occlusion therapy for 5 weeks	1 week of active conventional therapy	Post completed active conventional vision therapy
		Visit-I	Visit-II	Visit-III
Refraction		Bilateral plano	Bilateral plano	Bilateral plano
Cyclopegic refraction		+1.50 DS bilaterally	+1.50 DS bilaterally	+1.50 DS bilaterally
Cover uncover test		LDS for near and distance With unilateral amblyopia	Alternate divergence squint	Small exophoria for near and distance
Extra ocular movements		Full bilaterally	Full bilaterally	Full bilaterally
Near point convergence		10 cm	10 cm	6 cm
Near point accommodation		-	12 cm	6 cm
BSV	Grade I (SMP)	Intermittently Present.	Intermittently present 20° with 4R/L	Intermittently present 0
	Grade II (fusion)	Intermittently Present	15 to -20	0
	Grade III (near and distance stereopsis)	-	400 sec of arc negative	25 sec of arc 400 A
Magnitude of deviation	Near	Up gaze: 14 PD Primary gaze: 12 PD Down gaze: 10 PD	UP gaze: 18 PD Primary gaze: 12-14 PD Down gaze: 10 PD	UP gaze: 6-8 PD Primary gaze: 4-6 PD Down gaze: 4 PD
	Distance	18-20 PD	20 PD	6 PD
Worth's four dot test		Near 4 dots, distance 2 red	4 dots i.e., 1 red, 2 green, and 1 white	4 dots i.e., 1 red, 2 green and, 1 white
Accommodative convergence/ accommodation (AC/A ratio)		-	High (i.e., 8.8)	Slightly high i.e., 5.8
Positive fusional vergence		Nil	Nil	+50°

RESULTS

After 16 weeks of active conventional vision therapy with fusional vergence on synaptophore and continued patching of the dominant eye, amblyopia was treated up to 2.5 lines

with a deviation of 6 PD for near and distance. Taking into account that the patient had uniocular amblyopia, we decided to converge that amblyopic eye more as compared to normal eye on synaptophore by imposing positive fusional value (X+5) towards the amblyopic eye and the

resultant post-treatment outcomes was favorable in this case. The Patient had no hyperphoria in the right eye with Grade I and Grade II zero (i.e., normal) and normal near point of convergence (NPC) and near point of accommodation (NPA) (i.e., 6 cm). The end result of 4-month improvement of visual acuity is visible in left BCVA and Grade III stereopsis (Figure 1 and 2). In the follow-up session the alteration is noted in the near and distance deviation (Figure 3).

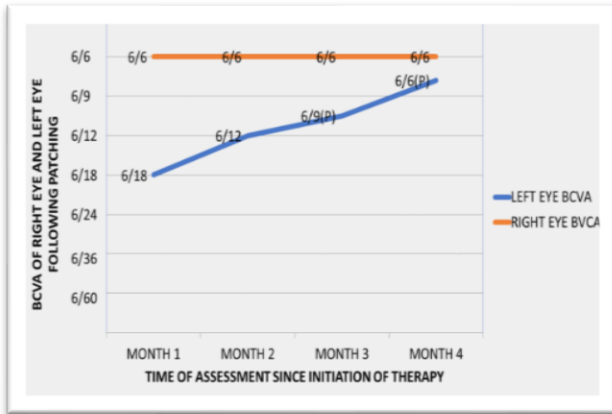


Figure 3: Enhancement of visual acuity following 4-month of vision therapy.

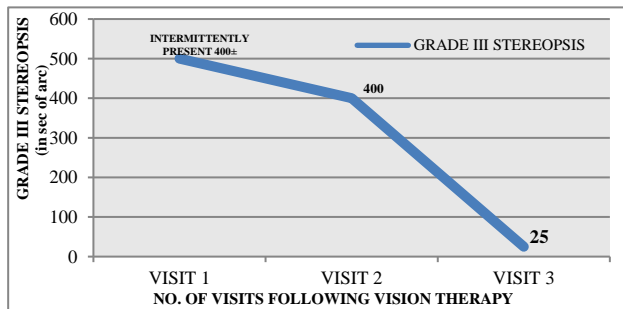


Figure 4: Improvements in grade III stereopsis.

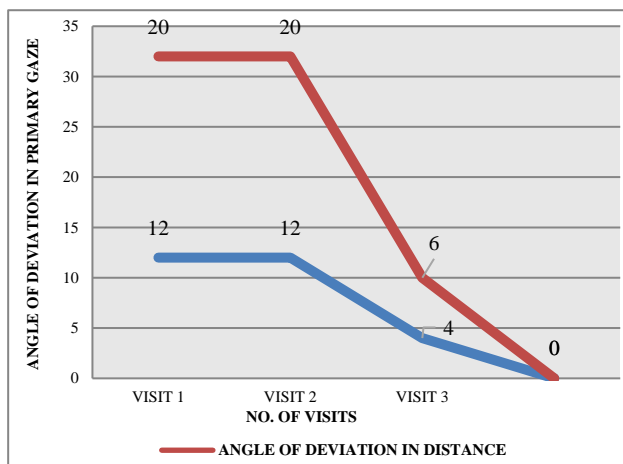


Figure 5: Change in angle of deviation in follow-up visits.

DISCUSSION

In this study to analyse the efficacy of vision therapy in impaired stereoscopic depth with amblyopia intermittent exotropia with divergence excess, we concluded an application of active vision therapy for the treatment of amblyopia and intermittent exotropia clinically and the sequential management of uniocular amblyopia give substantial long lasting improvement in visual acuity and binocular function for the patients of any age.

The RAF rule is an instrument used for determining the objective and subjective convergence points, examining accommodation in 1mm increments and determining the master eye. The RAF rule consists of a 50 cm long rule with a slider holding a rotating four-sided cube. Each side carries out separate functions. One side demonstrates diopters measurements from 20 to 2, the other side features a ruler from 5 to 50 centimeters, the next side tests ages 8 through 48, and the last side tests for convergence, normal, reduced, and defective. The first occupies a vertical line with a central dot for convergence fixation. The others provide a limited number of lines of near reading examples. Rest is provided for the cheek to ensure consistency and proper height for the patient. Several studies revealed more key consistency of the NPC when measured with the RAF Rule as compared to the pencil or finger. This tool is employed for both diagnosis and treatment purposes and is well established in clinical practice and researches.¹⁵

A brock string is a vision therapy tool used therapeutically by many researchers.¹⁶ It typically consists of a white flexible string of approximately 10-15 feet in considerable length with red, yellow and green colored small beads. The patient holds one end at the bridge of the nose and the therapist grasps another end. The patient is sought to carefully look at a bead 40 cm away from the nose, keep clear, notice the strings form an “X” that cross at the bead (physiological diplopia).

This specific technique is effective for the eye teaming; focusing, binocular awareness with the purpose is to see with both eyes simultaneously. Vectogram is a transparent polarized stereogram placed in the light- in vacant space using a polarized glass, stand or sit up straight, observe the 3-D effect when the two transparent cards slide opposite each other for convergence and divergence and are used for eye teaming, binocular awareness, SILO (small in large out).

Synaptophore or amblyoscope is a haploscopic device based on the mechanical dissociation of the 2 eyes by means of optical tubes. It typically helps in accurately measuring the possible angles of deviation and treating binocular vision anomalies by the conventional orthoptic method by using after images automatic flashing and Haidinger's brushes. The titmus fly test is purely based on screening for stereopsis. The fly target with a disparity of 3,600 seconds of an arc with response criterion requires

some form of reaction to the fly-wings 'floating' out of the test plane, like trying to pinch the apparent fly-wings.

The randot stereotest is a vectograph random dot stereo test used for detecting amblyopia, strabismus, suppression, and also for assessing stereoacuity. It can measure stereoacuity to 20 seconds of arc. It is more sensitive to monocular blur than real depth stereotests.^{17,18}

Asadi et al in his study also support orthoptic treatment that seems to be effective in reducing symptoms and improving signs of intermittent exotropia. In their study, the treatment was successful in 88.3% of patients in basic type, all patients in CI type and 88.8% in divergence excess group. Indeed, there are many reports of successful results of active vision therapy with only minimal amounts of occlusion.¹¹

Since the lack of binocular function is a key risk factor for persistent amblyopia, Levi et al said that assessing acuity as a recovery measure, it will also important to extend our evaluation to other visual deficits associated with amblyopia like the loss of stereoscopic depth perception may receive the most massive impact on the quality of life for the amblyopic patient, impairing the ability on visuomotor tasks and limiting career options. Moreover, adults who lack Stereopsis tend to be refractory to therapy.¹² McKee et al individuals with amblyopia, particularly strabismus, also exhibit oculo-motor deficits while Grant and Moseley reveal deficits of other visuomotor functions during the performance of fine motor tasks.^{13,14} Thus, developing novel methods of measuring trajectories for the recovery of binocular vision and visuomotor ability in both experimental animal models and humans may provide valuable insights into the success of future amblyopia treatments.

CONCLUSION

Divergence excess is asymptomatic in most acute cases because of good fusional reserve for near so proper routine eye examination of the patient for screening should be done. The case study concludes and supports the use of active conventional vision therapy as an integral part of the treatment of amblyopia and intermittent exotropia clinically. The rate of recovery of several monocular vision functions during 16 weeks of vision therapy was monitored, and they provide evidence of plasticity in the neural pathway at multiple sites in this adult exotropic amblyope. It also concludes that if a sequential management plan for treatment of Uniocular amblyopia is followed, it can yield substantial long-lasting improvement in visual acuity and binocular function for patients of any age.

ACKNOWLEDGEMENTS

The authors would like to thank HOD Dr. Satbir Singh HOD Ophthalmology from Regional Institute of Ophthalmology, PGIMS, Rohtak, Haryana for providing

all possible support and for permitting me to conduct this study under the department of ophthalmology. I extend my regards to the staff members of the hospital, for their guidance and timely help throughout the study. I acknowledge the subject who participated in this study.

Funding: No funding sources

Conflict of interest: None declared

Ethical approval: Not required

REFERENCES

1. Cooper J, Medow N. Intermittent Exotropia, basic and divergence excess type. *Binoc Vis Eye Muscle Surg*. 1993;8:185-216.
2. Kushner BJ. Exotropic deviations: A functional classification and approach to treatment. *Am Ortho J*. 1988;38:81-93.
3. Polat U, Ma-Naim T, Spierer A. Treatment of children with amblyopia by perceptual learning. *Vis Res*. 2009;49(21):2599-603.
4. Li RW, Young KG, Hoenig P, Levi DM. Perceptual learning improves visual performance in juvenile amblyopia. *Invest Ophthalmol Vis Sci*. 2005;46(9):3061-8.
5. Kapadia MK, Gilbert CD, Westheimer G. A quantitative measure for short- term cortical plasticity in human vision. *J Neurosci*. 1994;14(1):451-7.
6. Birnbaum MH, Koslowe K, Sanet R. Success in amblyopia therapy as a function of age: a literature survey. *Am J Optom Physiol Opt*. 1977;54(5):269-75.
7. Baek S. Role of exercise on the brain. *J Exercise Rehab*. 2016;12:380-5.
8. Li RW, Levi DM. Characterizing the mechanisms of improvement for position discrimination in adult amblyopia. *J Vision*. 2004;4(6):476-87.
9. Taub MB, Schnell PH. Vision therapy: Stories of success from around the world. Volume 1. Optometric Extension Program Foundation (OEPF); 2015.
10. Taub MB, Schnell PH. Vision therapy: Stories of success from around the world. Volume 2. Optometric Extension Program Foundation (OEPF); 2016.
11. Asadi R, Ghasemi-Falavarjani K, Sadighi N. Orthoptic treatment in the management of Intermittent Exotropia. *Iranian J Ophthalmol*. 2009;21(1):35-40.
12. Levi DM, Knill DC, Bavelier D. Stereopsis and amblyopia: A mini-review. *Vision Res*. 2015;114:17-30.
13. McKee SP, Levi DM, Schor CM, Movshon JA. Saccadic latency in amblyopia. *J Vis*. 2016;16(5):3.
14. Grant S, Moseley MJ. Amblyopia and real-world visuomotor tasks. *Strabismus*. 2011;19(3):119-28.
15. Burns D, Evans BJ, Allen PM. Clinical measurement of amplitude of accommodation: a review. *Optometry in Practice*. 2014;15(3):75-86.

16. Kergoat H, Law C, Chriqui E, Kergoat MJ, Leclerc BS, Panisset M, et al. Orthoptic Treatment of Convergence Insufficiency in Parkinson's disease: A Case Series. *Gerontol Geriatr Med*. 2017;3:2333721417703735.
17. Stereoacuity testing, ONE Network, American Academy of Phthalmology; 2014.
18. Odell NV, Hatt SR, Leske DA, Adams WE, Holmes JM. The effect of induced monocular blur on

measures of stereo acuity. *Journal of AAPOS*. 2009;13(2):136-41.

Cite this article as: Gupta R, Jangra R, Dubey G, Hooda R, Parmar N. Efficacy of vision therapy in impaired stereoscopic depth with intermittent exotropia (true divergence excess) with unilateral amblyopia: a case report. *Int J Community Med Public Health* 2020;7:773-8.